



**Real-Time Ultrasound Guidance Facilitates Femoral Arterial Access and Reduces Vascular Complications: FAUST (Femoral Arterial Access With Ultrasound Trial)**

Arnold H. Seto, Mazen S. Abu-Fadel, Jeffrey M. Sparling, Soni J. Zacharias, Timothy S. Daly, Alexander T. Harrison, William M. Suh, Jesus A. Vera, Christopher E. Aston, Rex J. Winters, Pranav M. Patel, Thomas A. Hennebry, and Morton J. Kern

*J. Am. Coll. Cardiol. Interv.* 2010;3;751-758

doi:10.1016/j.jcin.2010.04.015

**This information is current as of July 19, 2010**

The online version of this article, along with updated information and services, is located on the World Wide Web at:

<http://interventions.onlinejacc.org/cgi/content/full/3/7/751>



# Real-Time Ultrasound Guidance Facilitates Femoral Arterial Access and Reduces Vascular Complications

## FAUST (Femoral Arterial Access With Ultrasound Trial)

Arnold H. Seto, MD, MPA,\* Mazen S. Abu-Fadel, MD,† Jeffrey M. Sparling, MD,†  
Soni J. Zacharias, MD,† Timothy S. Daly, MD,† Alexander T. Harrison, MD,\*  
William M. Suh, MD,\* Jesus A. Vera, MD,\* Christopher E. Aston, PhD,‡  
Rex J. Winters, MD,§ Pranav M. Patel, MD,\* Thomas A. Hennebry, MB, BCH, BAO,†  
Morton J. Kern, MD\*

*Orange and Long Beach, California; and Oklahoma City, Oklahoma*

**Objectives** The aim of this study was to compare the procedural and clinical outcomes of femoral arterial access with ultrasound (US) guidance with standard fluoroscopic guidance.

**Background** Real-time US guidance reduces time to access, number of attempts, and complications in central venous access but has not been adequately assessed in femoral artery cannulation.

**Methods** Patients (n = 1,004) undergoing retrograde femoral arterial access were randomized 1:1 to either fluoroscopic or US guidance. The primary end point was successful common femoral artery (CFA) cannulation by femoral angiography. Secondary end points included time to sheath insertion, number of forward needle advancements, first pass success, accidental venipunctures, and vascular access complications at 30 days.

**Results** Compared with fluoroscopic guidance, US guidance produced no difference in CFA cannulation rates (86.4% vs. 83.3%, p = 0.17), except in the subgroup of patients with CFA bifurcations occurring over the femoral head (82.6% vs. 69.8%, p < 0.01). US guidance resulted in an improved first-pass success rate (83% vs. 46%, p < 0.0001), reduced number of attempts (1.3 vs. 3.0, p < 0.0001), reduced risk of venipuncture (2.4% vs. 15.8%, p < 0.0001), and reduced median time to access (136 s vs. 148 s, p = 0.003). Vascular complications occurred in 7 of 503 and 17 of 501 in the US and fluoroscopy groups, respectively (1.4% vs. 3.4% p = 0.04).

**Conclusions** In this multicenter randomized controlled trial, routine real-time US guidance improved CFA cannulation only in patients with high CFA bifurcations but reduced the number of attempts, time to access, risk of venipunctures, and vascular complications in femoral arterial access. (Femoral Arterial Access With Ultrasound Trial [FAUST]; NCT00667381) (J Am Coll Cardiol Intv 2010; 3:751–8) © 2010 by the American College of Cardiology Foundation

From the \*Department of Medicine, Division of Cardiology, University of California, Irvine Medical Center, Orange, California; †Department of Internal Medicine, Section of Cardiovascular Diseases, University of Oklahoma College of Medicine, Oklahoma City, Oklahoma; ‡University of Oklahoma Health Sciences Center, General Clinical Research Center, Oklahoma City, Oklahoma; and the §Memorial Heart Institute, Long Beach Memorial Medical Center, Long Beach, California. This work was supported by the Memorial Medical Center Foundation (Long Beach, California), the National Institutes of Health, National Center for Research Resources, General Clinical Research Center at University of Oklahoma (Grant M01-RR 14467), and a material research grant from Bard Access, Inc., Salt Lake City, Utah.

Manuscript received February 3, 2010; revised manuscript received March 17, 2010, accepted April 7, 2010.

Vascular complications are the most common complications of diagnostic and interventional catheterization procedures performed from the femoral approach, occurring in 1.5% to 4% of patients (1,2). Bleeding complications and transfusions have been associated with increased morbidity, mortality, and health care costs (2,3).

Access complications are associated with female sex, extremes of weight, renal insufficiency, anticoagulation, and the use of glycoprotein IIb/IIIa inhibitors (1,4). Multiple retrospective studies have associated inappropriate puncture locations with an increased risk of complications. Cannulation above the inguinal ligament is associated with retroperitoneal hemorrhage (5-7), whereas insertion below the common femoral artery (CFA) bifurcation is associated with pseudoaneurysm and arteriovenous fistula formation (8,9). Proper CFA cannulation is required for the safe deployment of most vascular closure devices.

The use of fluoroscopic guidance has been widely recommended, on the basis of the observation that 65% of femoral artery bifurcations occur below the inferior border of the femoral head (9,10), to potentially reduce complications (11). However, despite nonrandomized data supporting its use (12), 3 recent randomized trials failed to demonstrate a

benefit for fluoroscopic guidance in non-CFA cannulations or clinical complications compared with the use of anatomical landmarks alone (10,13,14).

Ultrasound guidance has been widely used for central venous access in the last decade. In multiple randomized trials and 2 meta-analyses, real-time US guidance has been shown to reduce complications, number of attempts, and time to access in central venous cannulation (15,16). Routine use of US guidance has been recommended by the National Institute of Clinical Effectiveness (U.K.) and Agency for Healthcare Research and Quality (U.S.) for central venous line placement (17,18) and has become the standard of care. Despite this, no large study of US guidance has been conducted for femoral arterial procedures.

We sought to define the utility of US guidance in femoral arterial access with a multicenter randomized controlled trial with the most modern equipment. We hypothesized that US guided access would be superior to conventional fluoroscopic guided access with regard to accuracy and related access site complications.

We sought to define the utility of US guidance in femoral arterial access with a multicenter randomized controlled trial with the most modern equipment. We hypothesized that US guided access would be superior to conventional fluoroscopic guided access with regard to accuracy and related access site complications.

## Methods

**Study design.** FAUST (Femoral Arterial Access With Ultrasound Trial) was a prospective, randomized, single-blinded trial conducted at 4 U.S. medical centers (1 private nonprofit, 2 university, and 1 government). The trial was

investigator-initiated, -designed, and -conducted. Research materials were supplied by the sponsor, who had no role in the design, analysis, or publication of the trial. The FAUST protocol was approved by the institutional review board of each participating medical center.

**Patient population.** Patients older than 18 years of age scheduled to undergo a diagnostic or interventional coronary or peripheral procedure from the retrograde femoral arterial approach were eligible for enrollment in the trial. Patient enrollment required the availability of a dual-trained primary operator, ultrasound machine, and research coordinator and thus was nonconsecutive.

Patients were excluded from the trial if they: 1) had nonpalpable femoral pulses; 2) had a creatinine of  $\geq 3.0$  mg/dl, unless already receiving dialysis; 3) had an ST-segment elevation myocardial infarction or unstable non-ST-segment elevation myocardial infarction; 4) were pregnant; or 5) were incarcerated. All enrolled patients gave written informed consent to be included in the trial.

**Device descriptions.** The Site Rite 5 and Site Rite 6 Ultrasound Systems (Bard Access, Inc., Salt Lake City, Utah) are equipped with variable 5- to 10-MHz linear array US transducers capable of imaging to a depth of up to 6 cm. The device has a large 12- × 13-inch screen that is easily seen across the catheterization table. The probe is covered with a clear disposable sterile cover supplied with US transmission gel. An optional needle guide (Product #9001C0212, Bard Access) mounts onto the probe and fixes the path of a standard 18-gauge needle in 3 dimensions.

The Acuson Cypress US machine (Siemens Medical Imaging, Malvern, Pennsylvania) was used for <5% of US procedures, when a Site Rite was unavailable. The 7L3 vascular transducer transmits at a variable 4.3/5.4/6.6 MHz, providing adequate imaging but without the benefit of a needle guide.

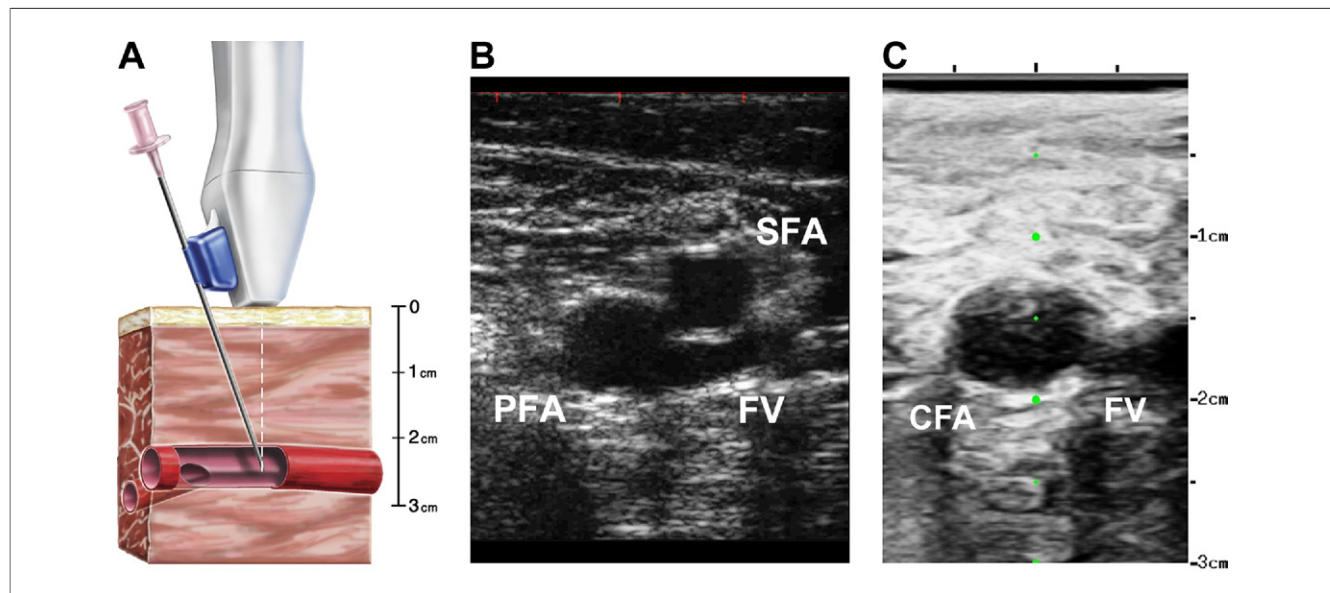
**Operator training.** Participating cardiology fellows and attending physicians received instruction on the study protocol and access techniques. For fluoroscopy patients, operators were instructed to attempt to cannulate the femoral artery at the center of the femoral head by marking its location with a radiopaque clamp and puncturing the skin 2 to 3 cm inferiorly. Training in US included lecture discussion and brief practice sessions on both gelatin models and live patients. Operators were instructed to aim for an insertion above the bifurcation with US (Fig. 1) and use anatomical landmarks to insert over the femoral head. A minimum of 3 proctored US-guided procedures were required before participation as a primary operator.

**Randomization.** Patients were randomized in a 1:1 fashion to either US or fluoroscopic guidance, with sealed envelopes balanced in groups of either 50 or 80 by each center. Patients were not randomized until a single dual-trained primary operator was assigned to their care.

### Abbreviations and Acronyms

**CFA** = common femoral artery

**US** = ultrasound



**Figure 1. Ultrasound Guidance Technique**

(A) The attached needle guide fixes the needle's angle of entry to intersect the vessel at the imaging plane 1.5 cm, 2.5 cm, or 3.5 cm below the skin, depending upon the guide chosen. The vessel bifurcation is kept inferior to the probe at the time of insertion. (B) The right femoral artery bifurcation is imaged in the axial plane, identifying the separation of the profunda femoral artery (PFA) and superficial femoral artery (SFA). Compression is used to differentiate arteries from the femoral vein (FV). (C) The probe is moved superiorly until the common femoral artery (CFA) is visualized. During needle advancement, the anterior wall of the vessel is kept under the central target line (green circles), which indicates the path of the needle.

**Procedure.** After being draped, all patients received manual palpation of anatomic landmarks: the anterior superior iliac spine, pubic symphysis, and the femoral pulse. For fluoroscopy patients, a radio-opaque marker was placed on the skin above the femoral head, and an anterior/posterior projection used to localize the femoral head relative to the marker. For US patients, the US machine was set up and draped, with transmission gel applied. If chosen by the operator, a needle guide was attached, and a needle was loaded. The US imaging was performed in the axial plane. The modified Seldinger technique was intended to be used in all cases.

The number of attempts required for sheath insertion and the number of accidental venipunctures was recorded by the operator and an independent observer. Attempts were defined as a forward motion separated by any withdrawal of the needle. If a fellow was involved, the attending physician was asked to allow 5 attempts before taking over the procedure. Time to access was recorded by lab staff from the first movement of the table for fluoroscopy or the first application of the US probe, until the sheath was successfully inserted. Time for sterile preparation of the field and US probe was not included. If an operator preferred to administer local anesthetic after localization by fluoroscopy or US, they were instructed to do so for all study patients regardless of randomization assignment. Nicking of the skin, dermatomy, or repeated fluoroscopy was performed by operator preference only.

Femoral angiograms were obtained in the 20- to 40-degree ipsilateral oblique position without cranial or caudal angulation. A second view was obtained only if the first failed to adequately visualize the position of the catheter relative to the CFA bifurcation. Placement of a vascular closure device, choice of antithrombotic drugs, and sheath size was solely according to the discretion of the attending physician.

**Follow-up.** All patients were examined by blinded nursing staff before discharge to assess for access site complications. Chart review and telephone contact was used to establish the presence of complications at 30 days.

**Study end points.** The primary end point of the study was successful cannulation of the CFA, defined as above the femoral bifurcation and below the origin of the inferior epigastric artery. The secondary end points included the following procedural outcomes: first pass success rate, total number of attempts required for access, rate of accidental venipunctures, and time to sheath insertion. The secondary safety end point was any access complication, defined as: hematoma  $\geq 5$  cm, pseudoaneurysm formation, retroperitoneal hemorrhage, arterial dissection, vessel thrombosis, noncoronary artery bypass graft-related access bleeding requiring transfusion, access site infection, or hemoglobin drop of  $\geq 3$  g/dl with an access source or  $\geq 4$  g/dl with an unknown source.

Prespecified subgroups included obese patients (body mass index  $\geq 30$  kg/m<sup>2</sup>), peripheral vascular disease patients

(ipsilateral stenosis of >50% by angiography), and patients with a high femoral artery bifurcation (occurring at or above the inferior border of the femoral head).

**Data analysis.** Two blinded investigators reviewed the femoral angiograms for proper CFA placement. A third senior blinded investigator adjudicated any disagreements. Angiograms were also analyzed for the position of the sheath, CFA bifurcation, and origin and most inferior reflection of the inferior epigastric artery relative to the femoral head. The CFA diameter was measured by comparison with the sheath, and the visible vessels were examined for evidence of significant peripheral vascular disease.

Clinical outcomes were reviewed by an independent blinded clinical events committee who had access to the relevant portions of medical records.

Collected data were analyzed on an intention-to-treat basis. The unpaired Student's *t* test or Wilcoxon rank sum test was used for continuous variables, and the chi-square test was used for proportions. The Fisher's exact test was used for clinical outcomes. A 2-tailed *p* value of < 0.05 was used for significance. Pre-specified subgroups were not subject to correction for multiple comparisons. Interactions were assessed with the Mantel-Haenszel test for homogeneity, and scatterplots were generated with STATA version 10 (StataCorp, College Station, Texas) software.

## Results

**Patient population.** Between April 2008 and February 2009, 1,015 patients were enrolled and randomized. Eleven patients no longer met the entry criteria by the time of their procedure and were excluded from the analysis but had no clinical events on follow-up. The remaining 1,004 patients were assigned to either fluoroscopic (*n* = 501) or US (*n* = 503) guidance and included in the analysis of intraprocedural and clinical outcomes.

Baseline patient and procedural characteristics were similar between the fluoroscopic and US groups except for tobacco use (Table 1). There was no difference in operator experience, on the basis of year of fellowship training (Online Appendix). Closure device use was more frequent in the US group (66.4% vs. 57.1%, *p* < 0.01). Needle guides were used in 463 of 503 (92%) of US procedures.

On the request of the attending physician 5 fluoroscopy patients crossed over to US, generally after 10 min and multiple attempts. A small number of patients (11 fluoroscopy, 4 US) did not have an adequate femoral angiogram performed, leaving 989 patients available for angiogram analysis. Successful telephone or clinic follow-up was completed in over 98% of patients in both groups.

**Angiogram analysis.** Successful CFA cannulation occurred in 86.4% of US-guided procedures, compared with 83.3% of fluoroscopy guided procedures (*p* = 0.17) (Fig. 2). Ultrasound lowered the rate of sheath insertion below the

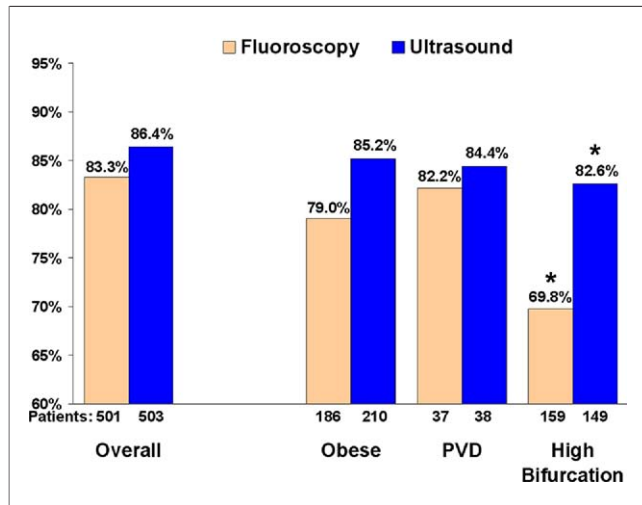
**Table 1. Baseline Patient and Procedural Characteristics**

Characteristic	Fluoroscopy (n = 501)	Ultrasound (n = 503)	p Value
Age, yrs	64.2 ± 11.4	63.5 ± 12.4	0.33
Male	366 (73.1)	371 (73.8)	0.80
White	329 (65.7)	352 (70.0)	0.14
Patient status			
Outpatient	254 (50.7)	265 (52.8)	0.53
Inpatient	171 (34.1)	148 (29.5)	0.11
Outpatient admitted after procedure	76 (15.2)	89 (17.7)	0.28
BMI (kg/m <sup>2</sup> )	29.4 ± 6.3	30.1 ± 7.2	0.11
Obesity (BMI >30)	186 (37.1)	210 (41.7)	0.13
Morbid obesity (BMI >40)	31 (6.2)	41 (8.2)	0.23
Hypertension	427 (85.2)	426 (84.7)	0.81
Hypercholesterolemia	387 (77.2)	405 (80.5)	0.20
Diabetes mellitus	182 (36.3)	203 (50.3)	0.19
Tobacco	184 (36.7)	226 (44.9)	0.008
Creatinine >2.0 mg/dl*	9 (1.8)	9 (1.8)	0.99
End stage renal disease	10 (2.0)	15 (3.0)	0.31
Ipsilateral PVD	45 (9.2)	45 (9.0)	0.92
CFA diameter, mm	6.49 ± 1.2	6.46 ± 1.2	0.68
Procedural characteristics			
Coronary angiogram	460 (91.8)	451 (89.7)	0.24
Peripheral angiogram	41 (8.2)	52 (10.3)	0.24
Intervention	161 (32.1)	155 (30.8)	0.65
Right heart catheterization	30 (6.0)	44 (8.7)	0.094
Sheath size	5.6 ± 0.8	5.6 ± 0.9	0.99
Fellow involved	470 (93.8)	468 (93.0)	0.62
Closure device used	286 (57.1)	332 (66.4)	0.004
Drugs used			
Heparin†	199 (39.7)	211 (41.9)	0.47
Glycoprotein IIb/IIIa inhibitor	38 (7.6)	38 (7.6)	0.99
Bivalirudin	40 (8.0)	38 (7.6)	0.80
Clopidogrel	251 (50.1)	236 (46.9)	0.31

Values are presented as n (%) or mean ± SD. \*Patients on dialysis excluded. †Heparin includes either unfractionated heparin and low molecular weight heparin.  
BMI = body mass index; CFA = common femoral artery; PVD = peripheral vascular disease, defined as >50% stenosis by angiography.

bifurcation of the CFA (7.0% vs. 11.8%, *p* < 0.01) but had a nonsignificant trend toward high sticks (6.6% vs. 4.9%, *p* = 0.25). Various alternative definitions of a high sheath insertion were used to analyze the angiograms, with no significant difference in the rate of CFA insertions (Table 2). Of the pre-specified subgroups, US showed a benefit in CFA cannulation only for the 31% of patients with a CFA bifurcation occurring above the inferior border of the femoral head (82.6% vs. 69.8%, *p* < 0.01).

**Intraprocedural outcomes.** Compared with fluoroscopic guidance, US guidance was associated with a reduced number of attempts, improved first pass success rate, reduced rate of venipuncture, and reduced time to access (Table 3). Ultrasound guidance with a needle guide was associated with a higher first pass success rate compared



**Figure 2. Common Femoral Artery Placement Success**

Ultrasound guidance did not demonstrate a significantly superior rate of sheath placement in the common femoral artery in the overall population or the obese or peripheral vascular disease (PVD) subgroups. Ultrasound guidance significantly increased common femoral artery sheath placements in the 31% of patients who had a femoral bifurcation over the femoral head. \* $p < 0.01$ .

with US without a needle guide (83.8% vs. 70%,  $p = 0.027$ ) (Online Appendix).

**Clinical outcomes.** Clinical access complications occurred in 17 of 501 (3.4%) patients in the fluoroscopy group, compared with 7 of 503 (1.4%) in the US-guided group ( $p = 0.041$ ) (Table 4). This result was driven by a significantly increased number of hematomas in the fluoroscopy group (11) versus the US group (3),  $p = 0.034$ . No patients suffered from access site infection, arteriovenous fistula formation, or retroperitoneal hemorrhage at 30 days. No patient had a significant decrease in hemoglobin in the absence of transfusion. One patient suffered from both a small hematoma and a deep venous thrombosis 1 day after discharge; otherwise, all complications were evident by hospital discharge. Among the hematoma complications, 7 (4 fluoroscopy, 3 US) were observed by physician or nursing

**Table 2. Sheath Placement According to Various Published Definitions of a High Stick**

Sheath Placement Above the CFA Bifurcation and	Fluoroscopy (n = 490)	Ultrasound (n = 499)	p Value
Below the origin of the IEA (6)	408 (83.3%)	431 (86.4%)	0.17
Below the most inferior reflection of the IEA (4)	391 (79.8%)	401 (80.4%)	0.82
Below the top one-third of the femoral head (5,7)	355 (72.4%)	361 (72.3%)	0.97
Below the top of the femoral head (6)	427 (87.1%)	447 (89.6%)	0.23
Anywhere over the femoral head (9)	407 (83.1%)	414 (83.0%)	0.98

Values are n (%). See references as noted.  
 IEA = inferior epigastric artery; other abbreviation as in Table 1.

**Table 3. Intraprocedural Outcomes**

Characteristic	Fluoroscopy (n = 500)	Ultrasound (n = 502)	p Value
Number of attempts	3.0 ± 3.2	1.3 ± 0.9	<0.000001
First pass success	232 (46.4%)	415 (82.7%)	<0.000001
Venipuncture	79 (15.8%)	12 (2.4%)	<0.000001
Number of arterial punctures	1.14 ± 0.43	1.09 ± 0.36	0.076
Mean time to insertion, s	213 ± 194	185 ± 175	0.016
Median time to insertion, s	148 (102–242)	136 (90–212)	0.003

Values are mean ± SD, n (%), or median (interquartile range).

staff in or near the catheterization laboratory, and complete blinding could not be verified. Exclusion of these complications increased the statistical significance of the result ( $p < 0.01$ ). There was no significant interaction between closure device use and bleeding complications ( $p = 0.81$ ).

**Learning curve.** Greater experience with the US guidance technique was nonsignificantly associated with a higher rate of successful CFA cannulation (Fig. 3). No pre-specified subgroup of US experience resulted in a significant improvement in CFA cannulation compared with fluoroscopic guidance; however, a trend was present. Increasing US experience was associated with a reduced time required for access with US guidance. A cut point was selected, on the basis of a scatterplot analysis (Online Appendix), to separate expert operators from novices. Operators with more than 10 procedures had a mean access time of 158 s, compared with 268 s for novice operators ( $p < 0.00001$ ).

## Discussion

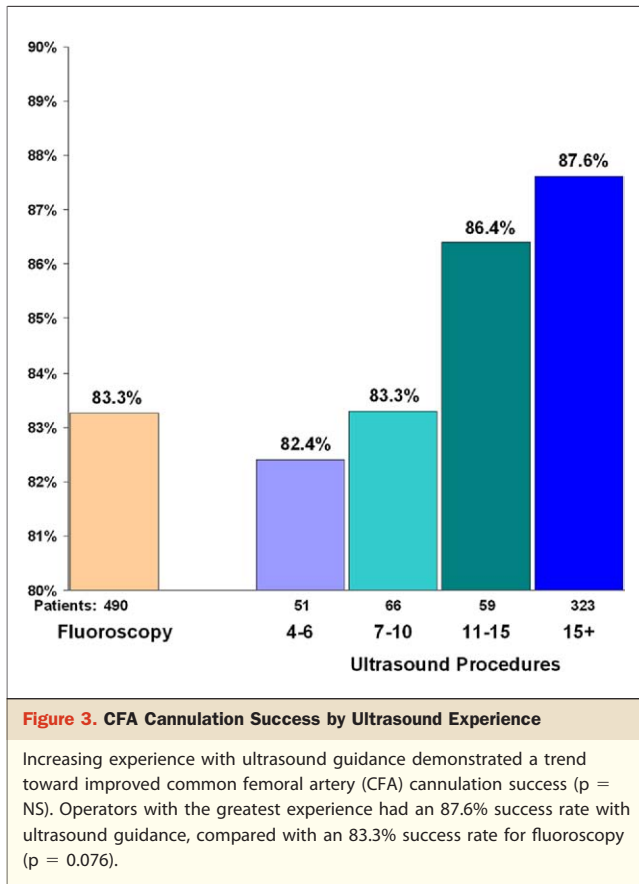
This multicenter randomized controlled study demonstrates that routine real-time US guidance of femoral arterial access does not improve the rate of CFA cannulation, except in patients with high CFA bifurcations.

Ultrasound guidance reduced the risk of vascular access complications by 59%, improved the first pass success rate to 82.7%, and nearly eliminated accidental venipunctures, while reducing the time required for access. The reduction in the rate of complications and average number of

**Table 4. Vascular Access Complications**

Complication	Fluoroscopy (n = 501)	Ultrasound (n = 503)	p Value
Hematoma ≥5 cm	11 (2.2%)	3 (0.6%)	0.034
Pseudoaneurysm	0	1	NS
Dissection	3	2	NS
Access bleeding, transfusion	2	1	NS
Hematoma with DVT	1	0	NS
Any complication	17 (3.4%)	7 (1.4%)	0.041

Values are n (%).  
 DVT = deep venous thrombosis.



attempts is similar to the 57% risk reduction and the reduction of 1.5 attempts seen in studies of internal jugular vein cannulation (15). Our study, the largest study of vascular access with US to date, extends the benefits to femoral arterial access.

Ultrasound guidance significantly decreased the number of low sticks, but a nonsignificant increase in high sticks resulted in only a trend toward an improved CFA cannulation rate. Our inclusion of operators with limited training in US guidance likely hindered our ability to show a difference in CFA cannulation success. Despite the learning curve with respect to this surrogate outcome, the other benefits of US guidance were evident with even the limited training available.

US guidance demonstrated an increased CFA cannulation rate in the 31% of patients with a CFA bifurcation occurring higher than the inferior border of the femoral head. Because this large subgroup of patients cannot be identified before catheterization in the absence of previous angiogram data, US guidance might necessarily be performed in all patients to achieve any CFA cannulation benefit. Ultrasound guidance could therefore be helpful where CFA cannulation is essential, namely for patients who require large sheaths for complex coronary or structural interventions or who require closure devices.

The surrogate CFA outcome results did not adequately reflect the benefit observed in actual complications and might reflect limitations in its utility. Femoral angiography is limited in its accuracy for locating the precise point of sheath insertion, as it is dependent on maintaining proper medial tension on the sheath, moving the sheath during the injection, and setting the appropriate degree of oblique angulation. Moreover, although there is agreement that sheath placement above the anatomical inguinal ligament increases the risk of retroperitoneal hemorrhage, the best angiographic correlates of the inguinal ligament are unclear and might vary from patient to patient. We tested our results according to several definitions of a high stick, none of which showed a significant difference between fluoroscopy and US.

The measurement of time to access in this study included time for injection of local anesthetic and imaging with fluoroscopy or US, in contrast to a previous study by Abu-Fadel et al. (10). The distributions of total attempts and time were positively skewed by difficult procedures in both fluoroscopy and US groups, with more outliers occurring with fluoroscopy (Online Appendix). Despite minimizing the effect of outliers, the median time to access showed a significant difference between fluoroscopy and US groups. This comparison excluded setup time for the US device to focus the measurement on the process of imaging and obtaining access. Sterile draping of the US probe and gel application can be performed by catheterization lab staff; however, if setup time is included the total time to use US guidance would be increased.

Closure device use was higher among patients receiving US guidance. This difference was mediated in part by a reduction in punctures below the CFA bifurcation, a reduction in multiple arterial punctures, and an increase in punctures at or above the top one-third of the femoral head with US. After adjustment for these and other factors, US guidance was not significantly associated with closure device use (Online Appendix). Closure devices did not reduce bleeding complications in a meta-analysis of randomized studies (19), although nonrandomized studies of more recent devices have suggested a benefit (1,20). In this study there was no significant interaction between closure device use and risk of bleeding; hence the clinical benefit seen with US guidance is not explained by the difference in closure device use.

Given the absence of significant differences in baseline patient and procedural parameters or CFA cannulation rates, the clinical benefit of US guidance is most likely mediated by a reduction in tissue and vessel trauma from multiple attempts and venipunctures. Ultrasound guidance is also more likely to achieve a true anterior wall puncture, which might allow for better arterial wall apposition and more appropriate seating of closure devices. Finally, manual pressure applied to the artery during a standard cannulation

might reduce its caliber, increasing the risk of a posterior or double wall puncture. With US guidance, any compression of the artery is both minimized and made visible during the procedure, potentially reducing the risk of a posterior wall puncture.

The only previous trial of US in retrograde femoral arterial access showed a modest benefit only in patients with obesity or a weak femoral pulse but was limited by a small sample size, a lack of data on CFA cannulation rates, and a total of 2 operators (21). The equipment used required a swivel arm to fix the probe, had no option for a needle guide, and is obsolete by today's standards.

The needle guide might be a critical tool for the US technique, because the needle is not generally visible until it traverses the axial imaging plane. Longitudinal imaging is an option to visualize the path of the needle, but generating such an image is difficult in the curved geometry of the groin, as is maintaining the needle in the precise plane of the US probe. Typical freehand axial US technique requires short forward and backward motions to project the path of the needle, which might limit its accuracy for novice operators. With a needle guide, if the image of the vessel is kept in the center of the screen, the vessel will be under the center of the US probe, and the needle will almost invariably insert at the point imaged.

The use of a needle guide in this study was not randomized, with only the most experienced operators attempting US guidance without one. Nevertheless needle guide use was associated with a higher first pass success rate. Future randomized studies would be necessary to confirm this difference.

**Study limitations.** Blinding of the operator and catheterization lab personnel to the study intervention was not possible. Despite the use of a second observer and lab timer, we cannot completely exclude a bias in the performance or measurement of the number of attempts, venipunctures, or time to access. Our results are specific to a high-quality US system with a needle guide and large screen and might not be generalizable to other systems. Because this trial was conducted at teaching hospitals, most of procedures involved cardiology fellows. However, US guidance maintained a benefit among procedures performed by attending physicians and interventional fellows (Online Appendix). We did not test the combination of fluoroscopy and US, which might increase the probability of inserting the sheath over the femoral head (10).

Finally, in this study the clinical benefit of US guidance was driven primarily by a reduction in hematomas  $\geq 5$  cm. Although 2 large contemporary randomized trials (ACUITY [Acute Catheterization and Urgent Intervention and Triage Strategy], HORIZONS-AMI [Harmonizing Outcomes With Revascularization and Stents in Acute Myocardial Infarction]) (22,23), included hematomas  $\geq 5$  cm as a component of non-coronary artery bypass graft-

related major bleeding, such hematomas were not associated with an increase in mortality in a recent pooled analysis of the same trials (hazard ratio: 1.30,  $p = \text{NS}$ ) (24). Hematomas were found to be associated with decreased hemoglobin counts but not with transfusions or mortality in the STEEPLE (SafeTy and Efficacy of Enoxaparin in Percutaneous coronary intervention patients, an international randomized Evaluation) trial (25). Many of these hematomas do not require intervention aside from prolonged manual pressure, bed rest, and observation; nevertheless, a cost-estimation analysis by Resnic et al. (3) found the attributable cost of such treatment to be \$1,399 per complication. Patient discomfort and the rate of premature discontinuation of antithrombotic agents would likely be increased from management of hematomas, but to our knowledge this has not been specifically studied.

**Cost-effectiveness.** We did not directly measure the costs associated with US guidance in this study. Ultrasound has been previously estimated by the National Institute for Clinical Excellence to save £2,000 for every 1,000 central venous procedures (26). For an incremental cost of disposables of \$17 per patient and an attributable cost of \$1,399 to treat a hematoma (3), we estimate that excluding initial hardware costs of \$17,000 US guidance could potentially save \$550 for every 50 patients in which it was used for femoral arterial access.

## Conclusions

In this multicenter randomized trial of femoral arterial access, US guidance facilitated successful arterial access and reduced clinical complications. The rate of sheath insertion into the CFA was increased in patients with a high CFA bifurcation but not in the overall population. Ultrasound guidance should be considered for any patient at high risk for a difficult access or complications.

## Acknowledgments

The authors thank the Clinical Events Committee: Joseph Babb, Craig Thompson, and Barry Uretsky. The authors also thank the catheterization laboratory staff and physicians at University of California-Irvine, Long Beach Memorial, Oklahoma Veteran's Administration, and Oklahoma University medical centers for their support. Dr. Robert Yeh provided statistical assistance with the manuscript.

**Reprint requests and correspondence:** Dr. Arnold H. Seto, Division of Cardiology, UC-Irvine Medical Center, 200 South Manchester Avenue, Suite 400, Orange, California 92868. E-mail: [arnoldseto@yahoo.com](mailto:arnoldseto@yahoo.com).

## REFERENCES

1. Tavaris DR, Gallauresi BA, Lin B, et al. Risk of local adverse events following cardiac catheterization by hemostasis device use and gender. *J Invasive Cardiol* 2004;16:459-64.
2. Ndrepepa G, Berger PB, Mehilli J, et al. Periprocedural bleeding and 1-year outcome after percutaneous coronary interventions. *J Am Coll Cardiol* 2008;51:690-7.
3. Resnic FS, Arora N, Matheny M, Reynolds MR. A cost-minimization analysis of the Angio-Seal vascular closure device following percutaneous coronary intervention. *Am J Cardiol* 2007;99:766-70.
4. Sherev DA, Shaw RE, Brent BN. Angiographic predictors of femoral access site complications: implication for planned percutaneous coronary intervention. *Catheter Cardiovasc Interv* 2005;65:196-202.
5. Farouque HM, Tremmel JA, Raissi Shabari F, et al. Risk factors for the development of retroperitoneal hematoma after percutaneous coronary intervention in the era of glycoprotein IIb/IIIa inhibitors and vascular closure devices. *J Am Coll Cardiol* 2005;45:363-8.
6. Ellis SG, Bhatt D, Kapadia S, Lee D, Yen M, Whitlow P. Correlates and outcomes of retroperitoneal hemorrhage complication percutaneous coronary intervention. *Catheter Cardiovasc Interv* 2006;67:541-5.
7. Tiroch KA, Arora N, Matheny M, Liu C, Lee TC, Resnic FS. Risk predictors of retroperitoneal hemorrhage following percutaneous coronary intervention. *Am J Cardiol* 2008;102:1473-6.
8. Altin RS, Flicker S, Naidech HJ. Pseudoaneurysm and arteriovenous fistula after femoral artery catheterization: association with low femoral punctures. *Am J Roentgenol* 1988;152:629-31.
9. Kim D, Orron DE, Skillman JJ, et al. Role of superficial femoral artery puncture in the development of pseudoaneurysm and arteriovenous fistula complicating percutaneous transfemoral cardiac catheterization. *Catheter Cardiovasc Diagn* 1992;25:91-7.
10. Abu-Fadel MS, Sparling JM, Zacharias SJ, et al. Fluoroscopy vs. traditional guided femoral arterial access and the use of closure devices: a randomized controlled trial. *Catheter Cardiovasc Interv* 2009;74:533-9.
11. Schnyder G, Sawhney N, Whisenant B, Tsimikas S, Turi ZG. Common femoral artery anatomy is influenced by demographics and comorbidity: implications for cardiac and peripheral invasive studies. *Catheter Cardiovasc Interv* 1;53:289-95.
12. Fitts J, Ver Lee P, Hofmaster P, Malenka D. Fluoroscopy-guided femoral artery puncture reduces the risk of PCI-related vascular complications. *J Invasive Cardiol* 2008;21:273-8.
13. Jacobi J, Schussler JM, Johnson KB. Routine femoral head fluoroscopy to reduce complications in coronary catheterization. *Proc (Bayl Univ Med Cent)* 2009;22:7-8.
14. Huggins CE, Gillespie MJ, Tan WA, et al. A prospective randomized clinical trial of the use of fluoroscopy in obtaining femoral arterial access. *J Invasive Cardiol* 2009;21:105-9.
15. Hind D, Calvert N, McWilliams R, et al. Ultrasonic locating devices for central venous cannulation: meta-analysis. *Br Med J* 2003;327:361-7.
16. Randolph A, Cook D, Gonzales CA, Pribble CG. Ultrasound guidance for placement of central venous catheters: a meta-analysis of the literature. *Crit Care Med* 1996;24:2053-8.
17. Rothschild JM. Ultrasound guidance of central venous catheterization. In: Wachter RM, editor. *Making Health Care Safer: A Critical Analysis of Patient Safety Practices*. Agency for Healthcare Research and Quality, 2001. Evidence Report/Technology Assessment, No. 43. AHRQ Publication No. 01-E058, Chapter 21: 245-53. Available at: <http://archive.ahrq.gov/clinic/ptsafety/chap21.htm>. Accessed October 16, 2009.
18. Guidance on the Use of Ultrasound Locating Devices for Placing Central Venous Catheters. National Institute for Clinical Excellence (UK), 2002. Technology Guidance No. 49. Available at: [http://www.nice.org.uk/nicemedia/pdf/Ultrasound\\_49\\_GUIDANCE.pdf](http://www.nice.org.uk/nicemedia/pdf/Ultrasound_49_GUIDANCE.pdf). Accessed October 16, 2009.
19. Koreny M, Riedmuller E, Nikfardjam M, Siostrzonek P, Mullner M. Arterial puncture closing devices compared with standard manual compression after cardiac catheterization: systematic review and meta-analysis. *JAMA* 2004;291:350-7.
20. Arora N, Matheny M, Sepke C, Resnic FS. A propensity analysis of the risk of vascular complications after cardiac catheterization procedures with the use of vascular closure devices. *Am Heart J* 2007;153:606-11.
21. Dudeck O, Teichgraber U, Podrabsky P, Haenninen EL, Soerensen R, Rieke J. A randomized trial assessing the value of ultrasound-guided puncture of the femoral artery for interventional investigations. *Int J Cardiovasc Imaging* 2004;20:363-8.
22. Stone GW, McLaurin BT, Cox DA, et al. Bivalirudin for patients with acute coronary syndromes. *N Engl J Med* 2006;355:2203-16.
23. Stone GW, Witzenbichler B, Guagliumi G, et al. Bivalirudin during primary PCI in acute myocardial infarction. *N Engl J Med* 2008;358:2218-30.
24. Mehran R, Pocock S, Nikosky E, et al. Impact of different bleeding types on mortality after PCI: results from a pooled analysis of the REPLACE-2, ACUITY, and HORIZONS-AMI trials (abstract). European Society of Cardiology Congress. Barcelona, Spain; 2009.
25. White HD, Aylward PE, Gallo R, et al. Hematomas of at least 5 cm and outcomes in patients undergoing elective percutaneous coronary intervention: insights from the safety and efficacy of enoxaparin in PCI patients, an international randomized evaluation (STEEPLE) trial. *Am Heart J* 2010;159:110-6.
26. Calvert N, Hind D, McWilliams RG, Thomas SM, Beverley C. Ultrasound for central venous cannulation: economic evaluation of cost-effectiveness. *Anaesthesia* 2004;59:1116-20.

**Key Words:** complications ■ ultrasound ■ vascular access.

## ▶ APPENDIX

For supplementary figures, tables, and data, please see the online version of this article.

**Real-Time Ultrasound Guidance Facilitates Femoral Arterial Access and Reduces Vascular Complications: FAUST (Femoral Arterial Access With Ultrasound Trial)**

Arnold H. Seto, Mazen S. Abu-Fadel, Jeffrey M. Sparling, Soni J. Zacharias, Timothy S. Daly, Alexander T. Harrison, William M. Suh, Jesus A. Vera, Christopher E. Aston, Rex J. Winters, Pranav M. Patel, Thomas A. Hennebry, and Morton J. Kern

*J. Am. Coll. Cardiol. Interv.* 2010;3;751-758  
doi:10.1016/j.jcin.2010.04.015

**This information is current as of July 19, 2010**

<b>Updated Information &amp; Services</b>	including high-resolution figures, can be found at: <a href="http://interventions.onlinejacc.org/cgi/content/full/3/7/751">http://interventions.onlinejacc.org/cgi/content/full/3/7/751</a>
<b>References</b>	This article cites 22 articles, 6 of which you can access for free at: <a href="http://interventions.onlinejacc.org/cgi/content/full/3/7/751#BIBL">http://interventions.onlinejacc.org/cgi/content/full/3/7/751#BIBL</a>
<b>Rights &amp; Permissions</b>	Information about reproducing this article in parts (figures, tables) or in its entirety can be found online at: <a href="http://interventions.onlinejacc.org/misc/permissions.dtl">http://interventions.onlinejacc.org/misc/permissions.dtl</a>
<b>Reprints</b>	Information about ordering reprints can be found online: <a href="http://interventions.onlinejacc.org/misc/reprints.dtl">http://interventions.onlinejacc.org/misc/reprints.dtl</a>

